

To Evaluate the Efficacy of Alvarado Score and Ultrasonography in Acute Appendicitis

Dr. V. Gaikwad, Dr. S. Murchite, Shambhav Chandra, P. Modi

Dept Of Surgery, D Y Patil Medical College, D.Y. Patil University, Kolhapur-416006, (India)

Abstract: Alvarado score is an objective assessment of right lower quadrant pain. Alvarado score is based on sophisticated statistical analysis of symptoms, signs and laboratory data in acute appendicitis. The score ≥ 7 indicates high probability of acute appendicitis. Practically speaking, it is equivalent to one's degree of clinical suspicion. Therefore this scoring system is used to reach the clinical diagnosis. It is considered that use of the scoring system to make the clinical diagnosis would allow uniformity as more than one senior surgical resident are involved in making the decision. Other studies have shown that Alvarado score has the accuracy of 88%. Graded compression ultrasonography in diagnosis of acute appendicitis has greatly improved the ability to diagnose acute appendicitis with ultrasound. Graded compression sonography plays an important role in reducing the number of negative surgical exploration for acute appendicitis. The accuracy offered by sonography should keep negative laparotomy ratio at approximately 10%.

Keywords: Alvarado score, Ultrasonography, Appendicitis

I. Introduction

Acute appendicitis is the acute inflammation of the appendix. Acute appendicitis is the most common cause of acute surgical abdomen. Acute appendicitis is one of the most commonest surgical emergencies with a lifelong risk of 7 %.⁽¹⁾

Alvarado in 1986 put forward a scoring system for diagnosing acute appendicitis and has been validated in adult surgical practice. The scoring system as described by Alvarado is based on three symptoms, three signs and two lab findings.

Alvarado score is simple to use and easy to apply. Alvarado scoring system is a dynamic one allowing observation and critical evaluation of the clinical picture. Its application improved diagnostic accuracy. It can reduce negative appendectomy rate to 0-5% without increasing morbidity and mortality⁽²⁾. However, this system is not a substitute for clinical judgement and just an aid in diagnosing acute appendicitis and assist in arriving at a conclusion whether a particular case should be operated or not, so that the number of negative laparotomies will be reduced.³

Ultrasonography is the most economical investigation to aid a clinician in diagnosing acute appendicitis. Graded compression ultrasonography in diagnosis of acute appendicitis has greatly improved the ability to diagnose acute appendicitis with ultrasound.

Ultrasonography is critically operator dependent and care to be taken to avoid over interpreting a technically inadequate examination. Graded compression sonography plays an important role in reducing the number of negative surgical exploration for acute appendicitis. The accuracy offered by sonography should keep negative laparotomy ratio at approximately 10% which is improvement over the rate achieved by instinct alone.⁴

II. Methodology

The present study was conducted in the Department of Surgery, D.Y. Patil Hospital and Research Centre, Kolhapur during the period of May 2011 to May 2016. 150 patients, who were admitted on clinical suspicion of acute appendicitis & operated for appendectomies were included in the study. The diagnosis was done by consultants of Dept. Of Surgery, D.Y.P. Hospital, Kolhapur using Alvarado score and Ultrasonography. Patients with Alvarado score 5 and above were operated. The patients underwent thorough evaluation by clinical examination, investigation & ultrasonography.

Depending on individual presentation of signs and symptoms, a score was calculated for each case of suspected appendicitis from 10 values (based on Alvarado Score system).

Alvarado Scoring System	
Score	
Symptoms	
Migratory Rif Form	1
Anorexia	1
Nausea/ Vomiting	1
Signs	
Tenderness In Rif	2
Rebound Tenderness In Rif	1
Elevated Temperature	1
Laboratory Findings	
Leucocytosis	2
Shift To Left Of Neutrophils	1
Total Score	10

Table-1: Alvarado scoring system

Score 1-4: Acute appendicitis, very unlikely, keep under observation.
Score 5-6: Acute appendicitis may be, for regular observation.
Score 7-8: Acute appendicitis, probable, operate.
Score 9-10: Acute appendicitis, definite, operate.

The appendix specimen was sent for histopathological examination. Histopathological diagnosis was considered as final. When ultrasonographically positive cases were histopathologically positive, the cases were true positive and ultrasonographically negative cases with histopathologically also negative cases were considered as true negative.

Histopathologically negative cases with ultrasonography positive cases were false positive cases and histopathologically positive cases with ultrasonography negative cases were false negative cases.

III. Results

Total abdominal pain cases suspected to have acute appendicitis	No. Of Cases Operated	No. Of operated cases found to have inflamed appendix
150	123	112

Table-2: case distribution

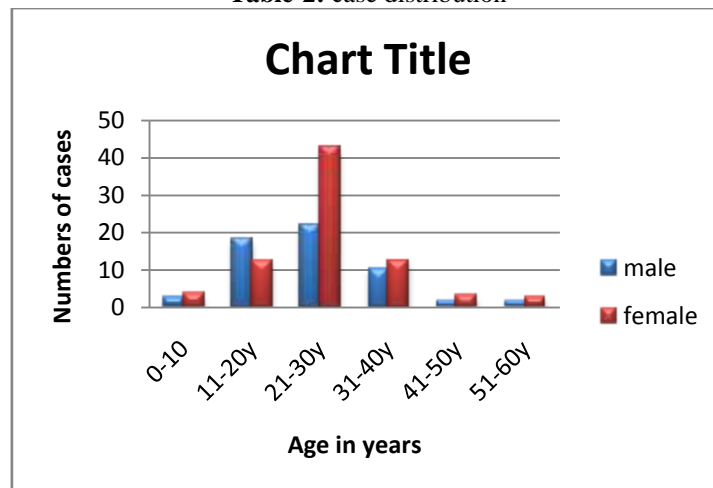


Figure 1 Age and sex distribution

In the present study, 79% patients with acute appendicitis were in the age group of 11-30 years. The fever, nausea/vomiting, pain at Mcburney`s point were found in 62, 84, 99% respectively which sustains their importance in diagnosis of acute appendicitis. Anorexia was found in 82%. The leucocytosis & neutrophilia were found in 74 & 80% respectively.

Pain was the commonest presenting symptom and was observed in all the cases (100%) in the present series. The classical shifting of pain from umbilical to right iliac fossa was present in 85% of cases. On clinical examination of the patient, tenderness at right Iliac Fossa in 98%. It was present when the inflammation was severe. Rebound tenderness was present in 79%.

Abdominal rigidity (7%) was due to perforated appendix or gangrenous appendicitis. Rovsing's sign was positive in 19%.

Psoas test was positive in 22% of patients whereas Obturator test was positive in 13% of retrocaecal appendix. Hyperaesthesia was present in 18%. 1.3% of cases had appendicular mass which were excluded from the study

In the present study the total leucocytic count was increased in 74%, and it was within normal range in 26%.

Number of operated patients		score 7-10	appendicitis	Normal appendix	Sensitivity
MALE	69	54	51	3	94.4%
FEMALE	53	29	26	3	89.5%
LE					

Table-3: sensitivity of Alvarado score

No. Of patients	Score			Mass in right iliac fossa	
	≥7-10	5-6	<5		
MALE	91	55	21	15	2
FEMALE	59	29	18	12	0
TOTAL	150	84	39	27	2

Table-4: Patient distribution and Alvarado score

Out of 150 cases studied 91 were males and 59 were females. Out of 91 male patients, score of >7-10 were 55; score of 5-6 patients were 21; 15 patients had score of <5 and 2 had mass in right iliac fossa. Out of 59 female patients; score of >7-10 were 29; score of 5-6 were 18; score of <5 were 12; these 27 patients of score <5 and patients with mass in RIF were observed in hospital and did not undergo surgery. The patients with mass in RIF were advised interval appendectomy.

Operative findings: Total of 123 patients were operated, out of which 76 were males; 47 were females. In patients having score of >7-10; 76 patients had acute appendicitis; 6 patients had normal appendix. Sensitivity for patients having score >7-10 was 92.7%.

Patients having score of 5-6; 26 patients had Acute appendicitis; 5 patients had normal appendicitis. Sensitivity for male patients having score 5-6 was 80.7%.

Ultrasonography signs of acute appendicitis	No. Of cases with percentage
Visualization of non compressible bowel str	34
Appendicular diameter >6mm	32
Diffuse hypoechogenicity	28
Lumen distended with iso/hyperechoic material	3
Visualization of appendicolith	1
Loss of wall layers	0
Peri-appendicular fluid collection	2
Visualization of peri-appendicular fat collection	0

Table-5: ultrasonographic signs of acute appendicitis

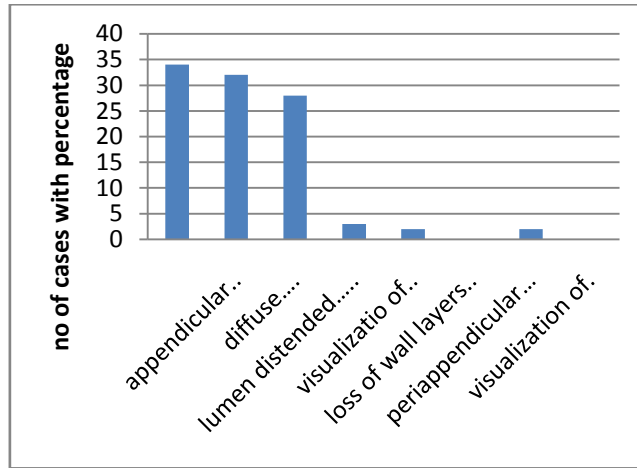


Fig -5: ultrasonographic signs of acute appendicitis

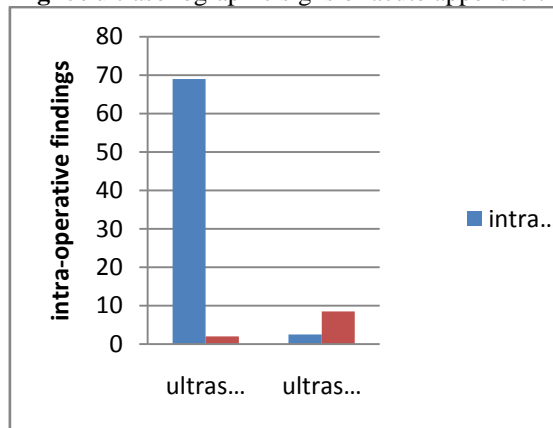


Fig-3: comparison of ultrasonography and intra-operative findings

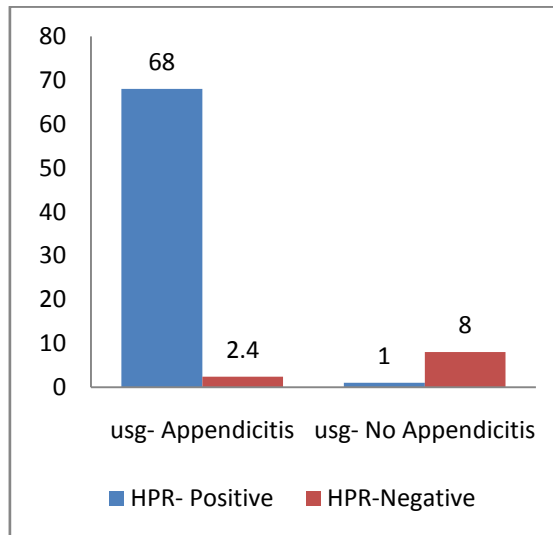


Fig-4: Comparison of ultrasonography and histological findings

IV. Discussion

Acute appendicitis is the most common cause of acute abdomen requiring surgical intervention. The Alvarado score assigns a numerical value to eight signs and symptoms associated with acute appendicitis.⁵ Ultrasonography has shown an extremely variable diagnostic accuracy in the diagnosis of acute appendicitis.⁶ While comparing ultrasound to the Alvarado score for the diagnosis of acute appendicitis, neither one is significantly advantageous. However the false positive rate is reduced to zero when both studies are positive and ultrasonography improved diagnostic accuracy along with the Alvarado score.

Pieper et al study done in 1962, shows estimated yearly incidence of 1.33 cases per thousand of population in females & 0.99 per thousand of population in males⁷. It appears to be more preponderant in females. In the present study the total leucocyte count was increased in 74%, and it was within normal range in 26%. In Pieper et al (1992) series, 66% had total count of 11.000 or more.

Sensitivity of patients having score >7-10 was 92.7%. Sensitivity of patients having score 5-6 was 80.7%. In Denizbasi A study shows 95.40% sensitivity for patients having score >7-10⁸. In our study, ultrasound shows 95.8% sensitivity & 88.9% specificity. Ida chan study showed 83% sensitivity & 95% specificity⁹.

V. Conclusion

Appendicitis is a disease of younger age group. Fever, nausea, vomiting were common symptoms of acute appendicitis whereas pain in right iliac fossa, neutrophilia, leukocytosis were common signs of commonest type of acute appendicitis as far as position of appendicitis was concerned.

Alvarado scoring system significantly reduces the number of negative laparotomies without increasing overall rate of appendicular perforation. It can work effectively in routine practise as an adjunct to surgical decision-making in suspicion of acute appendicitis. It is simple to use and easy to apply since it relies only on history, clinical examination and basic lab investigations.

Referneces

- [1]. A. Mohamed , N. Bhat. Avute appendicitis Dilemma of Diagnosis and Management. The Internet journal of surgery. 2009 volume 23 number 2.
- [2]. Murali Manohar R, Rahul Ingalcomparative study between Alvarado score and ultrasonography in correlation to histopathology report for diagnosis of acute appendicitis. International Journal of recent trends in science and technology, ISSN 2277-2812 e-ISSN 2249-8109, vol 13, issue 1, 2014 pp 117-120.
- [3]. Bassem Abou Merhi, Mahmoud Khali and Nabil Daoud: Comparison of Alvarado score evaluation and clinical judgement in acute appendicitis, Med Arch. 2014 feb; 68(1): 10-13.
- [4]. Marilyn Zelesco AMS: ultrasound of the vermiform appendix, educational supplement, Sound Effects, june 2001, p 32-37.
- [5]. Stephens PL, Mazzucco JJ:comparison of ultrasound and the Alvarado score for the diagnosis of acute appendicitis PMID: 10218289, Connecticut Medicine (1999), 63(3):113-140
- [6]. Pinto et al ;licensee BioMed Central Ltd. 2013: accuracy of ultrasonography in the diagnosis of acute appendicitis: review of the literature, Critical ultrasound journal 2013 5(suppl 1):s2 DOI:10.1186/2036-7092-5-s1-s2
- [7]. Pieper R, et al. Acta Chir Scand. 1982: the incidence of acute appendicitis and appendectomy. An epidemiological study of 971 cases. Acta Chir Scand. 1982;148(1):45-9
- [8]. Robert Ohle, Fran O'Reilly:The Alvarado score for predicting acute appendicitis: a systematic review. BMC Med. 2011;9:139
- [9]. Ida Chan, Simon G Bicknell, Marry Graham: utility and diagnostic accuracy of sonography in detecting appendicitis in a community hospital, American journal of roentgenology 184(6):1809-12. July 2005